



## **Treatment of A Case of Dysfunctional Uterinebleeding By Homoeopathic Medicine- A Case Report**

**Suhit Khanra**

Homoeopathic Medical College & Hospital, Sec. 26, Chandigarh, India.

### **Abstract**

A 47 years female patient suffering from Dysfunctional Uterine Bleeding since 21 days. Homoeopathic medicine Arsenic Album 200 was prescribed on basis of totality of symptoms, patients show improvement in shortest possible time.

**Key Word-** DUB, Homoeopathy, Case Tacking, Repertorisation.

**Corresponding Author:- Suhit Khanra,** Homoeopathic Medical College & Hospital, Sec. 26, Chandigarh, India.

**Received – 25/02/2021**

**Revised- 18/3/2021**

**Accepted – 30/03/2021**

### **INTRODUCTION**

The management DUB is a growing challenge globally in recent years. It has emerged as one of the leading causes of morbidity and mortality. The prevalence varies widely. The diagnosis to be done after exclusion of organic lesson.

DUB is clinical state of excess bleeding par uterus without any detectible pathological lesson such as tumor or any type of pelvic inflammatory response. Anovulatory cycle usually associated with excess menorrhagia is its common manifestation. It happens during premenopausal period due to hormonal imbalances. In about 20% cases DUB

found with ovulation but 80% cases it is with Anovulatory. This type of abnormal bleeding usually it happens with in absence of progesterone and endometrial growth happens due to influence of estrogen.

An ovular bleeding is usually due to the basic fault lye in ovaries in relation with less amount of secretion of gonadotropins there is also a slow increase In the secretion of estrogen but without any feedback inhibition of FSH.

**How to Cite this Article-** Khanra S., Treatment of A Case of Dysfunctional Uterine bleeding By Homoeopathic Medicine- A Case Report. TUJ. Homo & Medi. Sci. 2021;4(1):68-75.

As a result of this there is gradual rise in level of estrogen with a phase of amenorrhea for about six to eight weeks. After a period when estrogen level fall result in endometrial shedding with having bleeding.

### PATIENT DETAILS

**Name:** X

**Sex:** Female, **Age :** 47 Years,

**Final Diagnosis:** Dysfunctional uterine bleeding

**Symptoms:** Heavy per vaginum bleeding with Clots continued 21 days.

Pain in lower abdomen during menses.

**Medication:** Arsenic Album 200 .

**Clinical Procedure:** Case taking & Repertorisation.

**Objective:** Give relief in a gentle and shortest possible time period.

### Chief Complaints of Patient:-

- Heavy bleeding with clots in December 2020 and January 2021, bleeding continued for 21 days.
- Pain in lower abdomen during menses.
- H/o Irregular periods since 3-4 years.
- T/t Took allopathic treatment for 20 days in January.

### Menstrual History:-

- Menarche :- 14 years of age
- Complaints related to Menarche, if any: - Periods were normal and cycle was regular.

- Cycle presently: - Irregular with increased duration.

- Heavy bleeding with clots.

### Obstetric History:-

- Total number of pregnancies:- 03
- Abortions :- 02
- Children currently surviving :- 01

### Mental Generals:-

#### Will:-

1. Anxiety about child (about the future of the child)
2. Conscientiousness
3. Overthinking with negative thoughts.
4. Financial stress (Property dispute in Lucknow).
5. Extreme anxiety, constant look of worry, restlessness.
6. Patient very fastidious, everything must be systematically arranged and spotless.
7. Prostration and weakness.

**Understanding:** - Financial insecurity about future.

**Intellect:** - Good Memory (intelligent academically).

### Physical Generals :-

1. Thirst: - 2-3 liters/day. Drinks at short intervals. Desire normal tap water.
2. Stool: - stool unsatisfactory with burning sensation.
3. Irregular periods; Heavy bleeding with clots; In December 2020 and January 2021 bleeding lasts for 21 days. Pain in lower abdomen during menses.

4. Objective Symptom: - Yellowish discoloration of eyes.

5. Chilly patient.

6. Desire for warm drinks, fat, sweet.

7. Pathology:- USG Reports ( 11/01/2021)

Bulky uterus (approx. 10.8 × 5.8 cm in size) with heterochoic myometrium (maximum thickness measures 3.0 cm) Likely due to Adenomyosis Changes.

All well-defined heterochoic lesion is noted in the anterior myometrium measuring approx. 2.9 × 2.3 cm in size likely uterine fibroid.

Hemoglobin: - 9.7gm/dl.

### **Repertorization from Murphy Repertory**

Rubrics :-

1. Mind – Anxiety, general – children, in – about his children.
2. Mind – Pessimistic
3. Mind – FINANCIAL, loss of wealth or property, ailments from
4. Mind – MEMORY, general, active
5. Rectum – CONSTIPATION, general – insufficient, incomplete, unsatisfactory
6. Female – FIBROIDS, uterus

**Remedies:** - Ars – 9/4, Calc. – 6/4, Lach. – 7/4, Nux-V. – 8/4, Phos. – 7/4, Sulph. – 6/4, Aur. – 8/3, Calc-p. - 5/3.

### **Prescription and Follow Up-**

Arsenic Album 200, 3 doses at hourly intervals were prescribed on the 13th of January, 2021, and on her next visit (27th

January, 2021), she was feeling better overall. The following menstrual period was on time, and the complaints have not reoccurred since.

### **DISCUSSION**

Normally, regeneration of the endometrium is completed by the end of third day of menstruation. In irregular shedding, desquamation is continued for a variable period with simultaneous failure of regeneration of the endometrium. The possible explanations are:

- Incomplete withdrawal of LH even on 26th day of Cycle > incomplete atrophy of the corpus luteum > persistent secretion of progesterone.
- Persistent LH > inhibition of FSH > suppresses ripening of the follicle in the next cycle > less estrogen > less regeneration.

Endometrial sampling performed after 5th or 6th day of the onset of menstruation reveals a mixture of secretory and proliferative endometrium. There is total absence of any surface epithelium.

Irregular ripening of the endometrium: There is poor formation and inadequate function of the corpus luteum. Secretion of both estrogen and progesterone is inadequate to support the endometrial growth. As such, slight

bleeding occurs and continues prior to the start of proper flow.

The endocrine profile in the luteal phase shows persistent low level of urinary pregnanediol and that of plasma progesterone.

Endometrial study prior to or soon after spotting reveals patchy area of secretory changes amidst proliferative endometrium.

### **Anovular Bleeding**

**Menorrhagia:** Anovulatory bleeding is usually excessive. In the absence of growth limiting progesterone due to anovulation, the endometrial growth is under the influence of estrogen throughout the cycle. There is inadequate structural stromal support and the endometrium remains fragile.

Thus, with the withdrawal of estrogen due to negative feedback action of FSH, the endometrial shedding continues for a longer period in asynchronous sequences because of lack of compactness.

**Cystic glandular hyperplasia** (Syn: Metropathia hemorrhagica, Schroeder's Disease)- This type of abnormal bleeding is usually met in premenopausal women.

The basic fault may lie in the ovaries or may be due to disturbance of the rhythmic secretion of the gonadotropins. There is slow increase in secretion of

estrogen but no negative feedback inhibition of FSH. The net effect is gradual rise in the level of estrogen with concomitant phase of amenorrhea for about 6-8 weeks. As there is no ovulation, the endometrium is under the influence of estrogen without being opposed by growth limiting progesterone for a prolonged period. After a variable period, however, the estrogen level falls resulting in endometrial shedding with heavy bleeding. Bleeding also occurs when the endometrial growth have outgrown their blood supply. Due to increased endometrial thickness, tissue breakdown continues for a long time. Bleeding is heavy as there is no vasoconstrictor effect of PGF<sub>2</sub>o. Bleeding is prolonged until the endometrium and blood vessels regenerate to control it.

**Changes in the uterus:** There is variable degree of myohyperplasia with symmetrical enlargement of the uterus to a size of about 8-10 weeks due to simultaneous hypertrophy of muscles. The endometrial changes are classical. On naked eye examination, the endometrium looks tick, congested and often polypoidal.

It has been suggested that a patient's immune system has a major role to play in the onset and maintenance of obesity and its complications. This means that if deep and lasting changes for the better are to occur, then therapy must not

only help decrease weight but also change the immune status of the patient to a healthier one. This may be seen as changes in associated complaints.

Classical homeopathy regards an individual's immunological make up and medical history along with familial tendencies in order to determine the stress that triggered the chronic inflammatory state. With this in consideration the therapeutic approach is tailored to that particular individual and the result is resolution of the inflammatory state by the person's own immune system seen as overall betterment of the patient and not just one of the pathological conditions. Such general improvement in the co morbidities along with betterment in the main severe pathology by classical homeopathic therapy has been recorded before now. This is evidenced in the present case as well. The mechanism of action of the biologically active potentized remedies is not quite known. So far there are some hypotheses as may be seen in the Science of Homeopathy.

In our patient case, the autonomic nervous system dysfunction seemed to be central to all of the patient's suffering. The severe stress experienced by the patient seems to have upset the sympatho-vagal balance which resulted in obesity, hormonal imbalance, hypertension, and

vegeto-vascular dystonia. The initial disruption of our patient's health was caused by her severe grief. The remedies selected were those known to help bring about balance in conditions that result from grief and bereavement. The specific way in which the pathology develops and symptoms appear in response to deep seated grief has been recorded for this particular remedy provings and they have been of service where people have suffered from very long-standing depression and its co-morbidities. The repetition of low potencies therapies such as 15C must be made over a long period of time in order to see positive changes, as was seen in this case where the patient's autonomic dys-function responded within 5 months of the start of treatment, and the patient's hormonal state improved. Her weight reduced from 106 kg to 82 kg and her lipid levels improved even in the absence of a special diet or regimen and her menses regularized.

There is question regarding the mechanism of the applied remedy's action, and the evidence is not strong enough to clearly support results for this homeopathic remedy. However, such overall improvement from a therapy, especially without changes in any other parameter that may have caused the improvements, is encouraging and

suggests a need to further investigation into whether this case represents an exception or a rule. Controlled randomized trials are needed to establish the relevance of classical homeopathy in obesity and its co-morbidities and in autonomic dystonia as well

## CONCLUSION

This case of a female with dysfunctional uterine bleeding showed a benefit from homeopathy. It suggests the need to further evaluate, through larger studies, if any or all of these diagnoses may individually or collectively be amenable to classical homeopathic therapy.

## REFERENCES

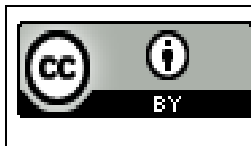
1. O'Neill S, O'Driscoll L. Metabolic syndrome: A closer look at the growing epidemic and its associated pathologies. *Obes Rev.* 2014;16(1):1–12. [PubMed] [Google Scholar]
2. Saltiel A, Olefsky J. Inflammatory mechanisms linking obesity and metabolic disease. *J Clin Invest.* 2017;127(1):1–4. [PMC free article] [PubMed] [Google Scholar]
3. Rethorst C, Bernstein I, Trivedi M. Inflammation, obesity, and metabolic syndrome in depression: analysis of the 2009–2010 National Health and Nutrition Examination Survey (NHANES). *J Clin Psychiatry.* 2014:e1428–32. [PMC free article] [PubMed] [Google Scholar]
4. Furukawa S, Fujita T, Shimabukuro M, et al. Increased oxidative stress in obesity and its impact on metabolic syndrome. *J Clin Invest.* 2004;114(12):1752–61. [PMC free article] [PubMed] [Google Scholar]
5. Babic R, Maslov B, Babic D, Vasilij I. The prevalence of metabolic syndrome in patient with posttraumatic stress disorder. *Psychiatr Danub.* 2013;25(Suppl. 1):45–50. [PubMed] [Google Scholar]
6. Bjorntorp P. Do stress reactions cause abdominal obesity and comorbidities? *Obes Rev.* 2001;2(2):73–86. [PubMed] [Google Scholar]
7. Vancampfort D, Correll C, Wampers M, et al. Metabolic syndrome and metabolic abnormalities in patients with major depressive disorder: A meta-analysis of prevalences and moderating variables. *Psychol Med.* 2013;44(10):2017–28. [PubMed] [Google Scholar]
8. Bulgakov M, Avtandilov A, Milovanova O. The role of prolonged stress and the functional state of the endothelium in the development of autonomic dystonia syndrome. *Neuroscience and Behavioral*

- Physiology. 2017;47(7):791–94. [Google Scholar]
9. Lobzin V, Poliakova L, Shiman A, Zavodnik A. [Treatment of autonomic vascular dystonia by combined physiotherapy methods] *Vrach Delo*. 1989;3:2–23. [in Russian] [PubMed] [Google Scholar]
  10. Vein A, Iakhno N, Kulikovski V, Mazhukin V. [Characterization of the status of nonspecific brain systems in cerebral autonomic-vascular crises and neurogenic syncope] *Zh Nevropatol Psikhiatr Im S S Korsakova*. 1981;81(7):988–94. [in Russian] [PubMed] [Google Scholar]
  11. Zotov D, Isakov V. The features of hemodynamic support of exercise stress in patients with neurocirculatory dystonia. *Pediatrician (St Petersburg)* 2018;9(1):49–53. [Google Scholar]
  12. Sympathoadrenal crisis: symptoms, treatment. *Medicine*. 2018 Available from: <http://medicine-en.info/neurology/sympathoadrenal-crisis-symptoms-treatment.html>. [Google Scholar]
  13. Isaev D, Efremov K. [Psychogenic factors involved in the formation of vegetovascular dystonia of a hypertonic type in children] *Zh Nevropatol Psikhiatr Im S S Korsakova*. 1983;83(10):1548–52. [in Russian] [PubMed] [Google Scholar]
  14. Peterson H, Rothschild M, Weinberg C, et al. Body fat and the activity of the autonomic nervous system. *N Engl J Med*. 1988;318(17):1077–83. [PubMed] [Google Scholar]
  15. Molfino A, Fiorentini A, Tubani L, et al. Body mass index is related to autonomic nervous system activity as measured by heart rate variability. *Eur J Clin Nutr*. 2009;63(10):1263–65. [PubMed] [Google Scholar]
  16. Vithoukcas G, Carlino S. The “continuum” of a unified theory of diseases. *Med Sci Monit*. 2010;16(2):SR7–15. [PubMed] [Google Scholar]
  17. Vithoukcas G. Levels of health. Athens: International Academy of Classical Homeopathy; 2017. [Google Scholar]
  18. Mahesh S, Mallappa M, Vithoukcas G. Embryonal carcinoma with immature teratoma: A homeopathic case report. *Complement Med Res*. 2018;25(2):117–21. [PubMed] [Google Scholar]
  19. Mahesh S, Mallappa M, Vithoukcas G. Gangrene: Five case studies of gangrene, preventing amputation through Homoeopathic therapy. *Indian*

- Journal of Research in Homoeopathy. 2015;9(2):114. [Google Scholar]
20. Mahesh S, Mallappa M, Tsintzas D, Vithoukas G. Homeopathic treatment of vitiligo: A report of fourteen cases. *Am J Case Rep.* 2017;18:1276–83. [PMC free article] [PubMed] [Google Scholar]
21. Tenzera L, Djindjic B, Mihajlovic-Elez O, et al. Improvements in long standing cardiac pathologies by individualized homeopathic remedies: A case series. *SAGE Open Med Case Rep.* 2018;6 2050313X1879281. [PMC free article] [PubMed] [Google Scholar]
22. Vithoukas G, Tiller W. *The science of homeopathy.* Athens: International Academy of Classical Homeopathy; 2009. [Google Scholar]
23. Oberai P, Balachandran I, Janardhanan Nair K, et al. Homeopathic management in depressive episodes: A prospective, unicentric, non-comparative, open-label observational study. *Indian Journal of Research in Homoeopathy.* 2013;7(3):116. [Google Scholar]
24. Kent J. *Lectures on homœopathic materia medica.* New Delhi: Jain Pub Co; 2012. [Google Scholar]

**Conflict of Interest: None**

**Source of Support: Nil**



**This work is licensed under a  
Creative Commons Attribution  
4.0 International License**

